

# Identification of Gastric Cancer from Speckle Patterns

C.A. ANDRADE-ERASO<sup>a</sup>, M. PATIÑO-VELASCO<sup>a</sup>, J. VÁSQUEZ-LÓPEZ<sup>a,b</sup>, J. LEÓN<sup>c</sup>,  
G. BOLAÑOS-PANTOJA<sup>d</sup> AND M. TRIVI<sup>e</sup>

<sup>a</sup>Grupo de Óptica y Laser, Departamento de Física, Universidad del Cauca, Popayán, Colombia

<sup>b</sup>Departamento Morfología, Facultad de Ciencias de la Salud, Universidad del Cauca, Popayán, Colombia

<sup>c</sup>Centro de Investigaciones en Ingeniería y Organizaciones, Grupo de Investigaciones en Ciencias Aplicadas  
Universidad Autónoma de Bucaramanga, Bucaramanga, Colombia

<sup>d</sup>Grupo de Física de Bajas Temperaturas, Departamento de Física, Universidad del Cauca, Popayán, Colombia

<sup>e</sup>Centro de Investigaciones Ópticas (CONICET La Plata - CIC) and UID Optimo, Dpto. Ciencias Básicas  
Facultad de Ingeniería, Universidad Nacional de La Plata, Casilla de Correo 3, 1897 Gonnet-La Plata, Argentina

Speckle technique is based on the light intensity distribution randomly formed when a laser light is reflected on a rough surface, creating a pattern of illuminated grains (constructively) and dark (destructive) on scales of  $1 \mu\text{m}$ . When the samples are displaced or deformed, the speckle pattern is altered. In this paper we present speckle patterns obtained from samples of gastric mucosa that is physically altered for the carcinogenesis process. Biopsies were studied with different diagnoses and were grouped according to the characteristics of speckle patterns. Speckle patterns were obtained by illuminating the samples with green laser. Morphological parameters of the speckle patterns reveal existence of 3 descriptors: the average grain size, hydraulic radius and the radio of the Weddel disc, which showed a high, intermediate and low value. The comparison shows agreement between the histopathological diagnosis and the values obtained by the speckle technique, making this technique emerge as a new classification system for quantitative diagnosis of precancerous lesions.

PACS: 78.68.+m, 42.87.-d, 87.50.W-

## 1. Introduction

The speckle phenomenon occurs when a highly coherent light as the laser interacts with a rough surface on the scale of the wavelength (i.e. changes in the surface of  $0.5 \text{ mm}$ ) [1]. When this surface is illuminated with laser light, scattered light has a particular intensity distribution, making the surface would fall with this fine grain structure with light and dark spots (Fig. 1) [2].

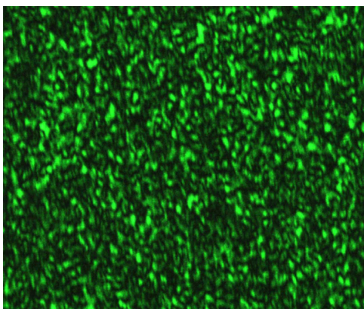


Fig. 1. Speckle pattern obtained by illuminating a sample of biological tissue.

Multiple scattered coherent waves with random amplitudes and phases meet at a point of observation in space and produce a Gaussian intensity distribution. The bright spots are produced by constructive interference and dark spots by destructive interference [3].

The intensity in the pattern due to a decreasing exponential distribution

$$P_I(I) = \frac{1}{\langle I \rangle} \exp\left(-\frac{I}{\langle I \rangle}\right), \quad (1)$$

where  $\langle I \rangle$  is the average intensity. The highest probability of the intensity values is zero, i.e. dark spots.

The phase is given by a uniform probability distribution, distributed in the interval  $(-\pi, \pi)$ :

$$P(\Phi) = \frac{1}{2\pi} \quad \text{for} \quad -\pi \leq \Phi \leq \pi. \quad (2)$$

An important parameter in a speckle pattern is the speckle grain size, which depends on the optical configuration of the system, the wavelength and the area of study [4]. However, if the optical systems remain unchanged, the speckle grain is a descriptor that characterizes the structural properties of the sample being illuminated. This is the case of tissue from gastric mucosa. Samples are in various states of degradation caused by carcinogenesis process, which affects the physical properties as density and cell size. The evidence, by pathological and epidemiological studies has provided a model of human gastric carcinogenesis following sequential stages: chronic gastritis atrophy, intestinal metaplasia and gastric dysplasia [5, 6]. The updated Sydney system proposed the use of visual analogue scale as a reference standard for classification and grading of precancerous gastric lesions [7]. This semiquantitative scoring system is

severely limited by interobserver variability [8]. Therefore, it is interesting to explore and optimize other quantitative techniques for the diagnosis of gastric lesions. This research studies the morphological changes in the speckle pattern as an indicator of natural history of gastric cancer.

## 2. Methodology

The statistical properties of the speckle patterns were used to characterize the gastric mucosa illuminated by a green laser (25 mW power, wavelength 532 nm) and the free propagation speckle patterns were acquired using a CCD SONY® DSW-910CR connected to a PC and analyzed using Visual C++ software and OPEN CV library (Fig. 2). The static speckle patterns were analyzed on histopathology slides from fifteen subjects that underwent endoscopic biopsy with three different confirmed histologic diagnoses of multifocal atrophy gastritis, intestinal metaplasia or gastric dysplasia. Three 4  $\mu\text{m}$  thick histologic sections were obtained from each biopsy fragment.

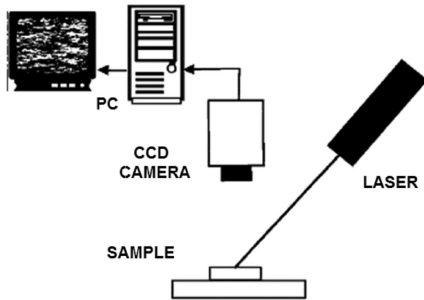


Fig. 2. Experimental setup of the speckle technique in free propagation configuration.

Three morphological parameters of the speckle patterns were analyzed: the grain size of speckle, the hydraulic radius (the relationship between area and perimeter of each speckle grain) and the Waddell disk radius (the diameter of a disk with the same area of each speckle grain). We studied gastric antral biopsies from the patients and formed groups following the corresponding speckle shape features. Results were compared with the traditional histopathological diagnosis technique with the objective to validate the effectiveness of the speckle image technique for the classification of gastric mucosa correlated to the carcinogenesis process.

## 3. Results and discussion

After the execution of processes to improve the image by digital filtering, average values of the three morphological parameters were obtained from 15 patients diagnosed with gastric atrophy, intestinal metaplasia or gastric dysplasia. Each value is the average of 3 slides taken for each patient. The obtained values for the speckle grain size,

the Waddell disk diameter and the hydraulic radius reveal the existence of three distinct groups based on a Bayesian analysis. High values for gastric atrophy, intermediate for intestinal metaplasia and low values for gastric dysplasia are shown in Fig. 3.

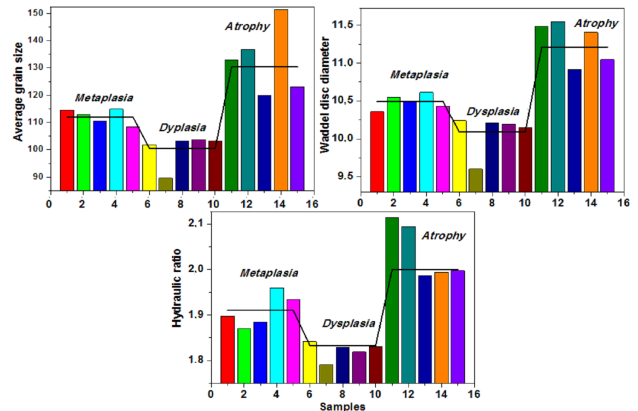


Fig. 3. Speckle grain size, the Waddell disk diameter and the hydraulic radius for speckle image obtained by biopsies of 15 patients diagnoses with gastric atrophy, intestinal metaplasia and gastric dysplasia.

All descriptors depend on speckle grain. To account for these results it is necessary to analyze the dependence of the speckle grain with respect to the illuminated area. Theoretically speckle grain is inversely proportional to the illuminated area [4, 9]. In the case of gastric mucosa, the biological carcinogenesis processes leading to a reduction cell causing the speckle grain size increase or decrease. The process of gastric atrophy leads to decrease of the oxyntic gland size [10], which are the dispersive center of the gastric tissue. This causes a decrease in the effective area illuminated, resulting in an increase in the speckle grain size. The opposite phenomenon happens with gastric dysplasia. In this case, increased amorphous glands are presented, including the agglomeration of cells that have completely lost their morphology [11]. Increasing the size of the dispersive centers in the gastric mucosal tissue decreases the speckle grain size, as a result of increasing the effective illuminated area. In the case of intestinal metaplasia the tissue is replaced by another that resembles the intestinal tissue. On the one side there is a process of elongation in the epithelium, which in principle would lead to a decrease in grain size compared with the gastric atrophy [12]. However, this effect on the gastric mucosa with intestinal metaplasia called vacuolization (the appearance of vacuoles (circles) in the glands) [13] makes the dispersive medium smaller, leading to increases in speckle grain size. The combined effect in intestinal metaplasia is causing intermediate speckle grain size.

## 4. Conclusion

Optical speckle assembly in free propagation configuration for the analysis of gastric mucosa biopsies have

been proposed in this paper. Three physical parameters (speckle grain size, waddle disk diameter and hydraulic ratio) from the morphological characteristics of speckle patterns were able to identify and classify the gastric carcinogenesis following sequential stages: chronic gastritis, atrophy, intestinal metaplasia and dysplasia. The comparison shows agreement between the histopathological diagnosis and the speckle analysis, making the speckle technique emerge as a new classification system for quantitative diagnosis of cancerous and precancerous lesions.

### Acknowledgments

These researches are performed with grants of Universidad del Cauca (Physics Department, Morphology Department), in particular the Vicerrectoría de Investigaciones for their support in carrying out work, which is part of the project "Optical characterization technique using biospeckle of human tissue samples with carcinogenesis" ID 3069 and BPIN 0020-05492-0000. The authors also want to acknowledge the great contribution of the group of Analisis Poblacional de Cáncer (Universidad del Valle, Colombia) and ANPCyT, CONICET, CIC and UNLP (Argentina).

### References

- [1] *Laser Speckle and Related Phenomena*, Ed. J.C. Dainty, Springer Verlag, Berlin 1975.
- [2] J.W. Goodman, *Speckle Phenomena in Optics: Theory and Applications*, Roberts and Co. Publ., USA 2007.
- [3] J.D. Briers, *Opt. Quant. Electron.* **10**, 364 (1978).
- [4] H.J. Rabal, R.A. Braga Jr., *Dynamic Laser Speckle and Applications*, CRC Press, Argentina 2009.
- [5] J.C. Adrada, F.H. Calambás, J.E. Díaz, D.O. Delgado, C.H. Sierra, *Rev. Col. Gastroenterol.* **23**, 344 (2008) (in Spanish).
- [6] P. Correa, *Cancer Res.* **52**, 6735 (1992).
- [7] J. Guarner, R. Herrera-Goepfert, A. Mohar, L. Sánchez, D. Halperin, C. Ley, *Hum. Pathol.* **30**, 1431 (1999).
- [8] L.E. Bravo, J.C. Bravo, J.L. Realpe, G. Zarama, M.B. Piazuolo, P. Correa, *Colomb. Med.* **56**, 58 (2008).
- [9] L.A. Terry, E.J. Harvey, R.A. Weeks, *Appl. Opt.* **33**, 8240 (1994).
- [10] R.M. Genta, *Ital. J. Gastroenterol. Hepatol. Suppl.* **30**, S273 (1998).
- [11] J. Misdraji, G.Y. Lauwers, *Semin. Diagn. Pathol.* **19**, 20 (2002).
- [12] G.A. Rothery, D.W. Day, *J. Clin. Pathol.* **38**, 613 (1985).
- [13] S.C. Ming, *Intestinal Metaplasia: Its Heterogeneous Natural and Significance in Precursors of Gastric Cancer*, Ming SC Praeger Publ., New York 1984, p. 141.